

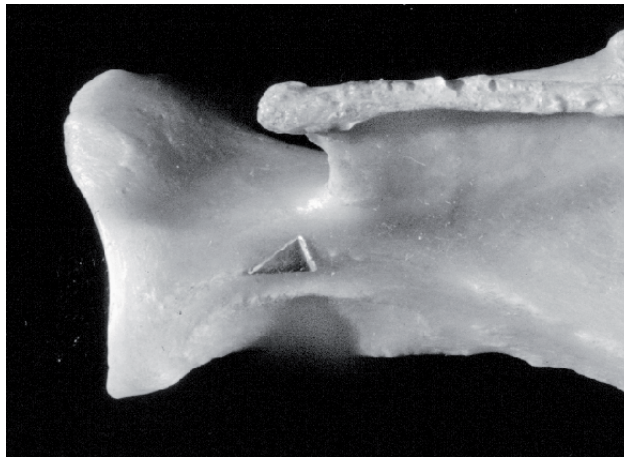
## Appendix A - The Locations of the Scan-Sites

---

Bone landmarks are taken from Steele and Bramblett (1988) and bone orientations are taken from Von den Driesch (1976)

### Scapula

One measurement only: Just proximal of the most proximal point of the glenoid cavity at the deepest (medio-laterally) part of the bone.

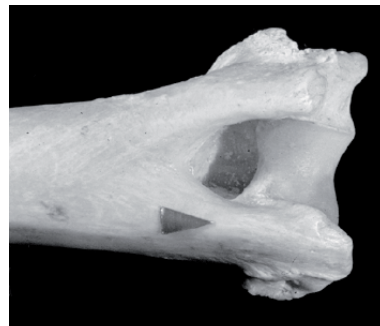
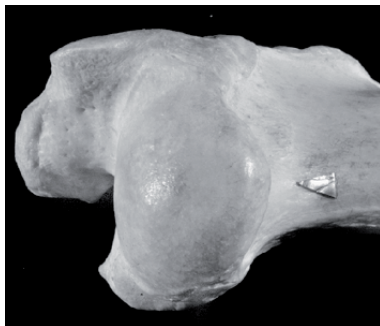


### Humerus

Proximal: The most caudally protruding ridge of the surgical neck, just distal of the most distal part of the proximal articulation.

Distal: Just proximal of the distal fusion line on the caudal side of the lateral epicondyle.

Shaft: Halfway between the proximal and distal scan-sites, at the midpoint medio-laterally.

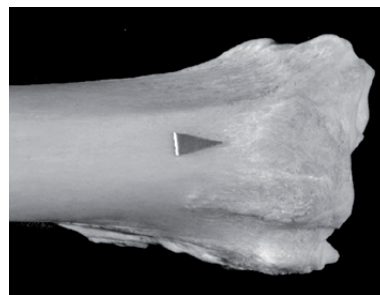
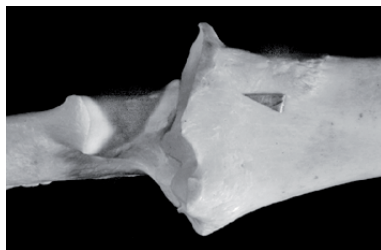


## **Radius**

Proximal: Just distal of the most distal point of the articulation for the trochlea and immediately medial of the fused ulna (or position of ulna – as indicated by the presence of a “scar” - where the ulna is unfused).

Distal: Just proximal of the distal fusion line, in the medio-lateral centre of the groove for the extensor pollicis longus.

Shaft: Halfway between the proximal and distal scan-sites, just medial of the ulna shaft (or scar where the ulna is unfused).

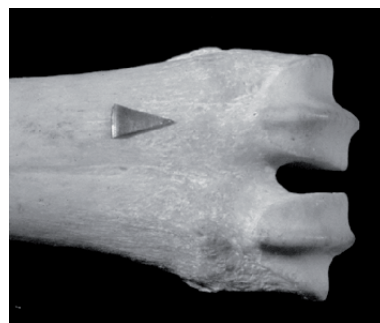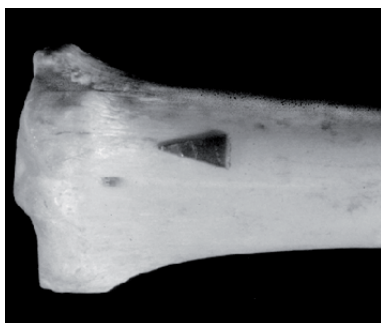


## **Metacarpal**

Proximal: Just distal of the proximal articular surface, at the deepest (dorso-palmar) point of the bone (this is also the deepest – dorso-palmar - point of the 3<sup>rd</sup> metacarpal).

Distal: Just distal of the distal fusion line, at the midpoint (medio-laterally) of the 3<sup>rd</sup> metacarpal.

Shaft: Halfway between the proximal and distal scan-sites, at the medio-lateral centre of the 3<sup>rd</sup> metacarpal.

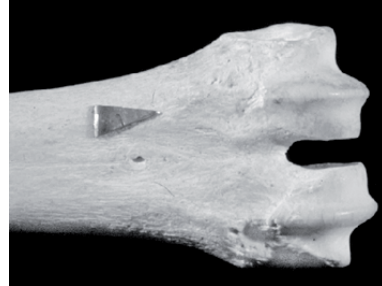
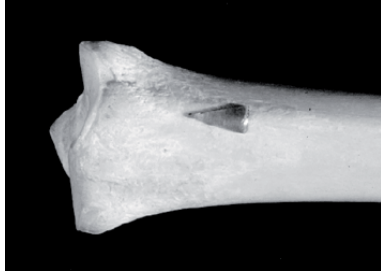
## **Metatarsal**

Proximal: Just distal of the proximal articular surface, at the deepest (dorso-palmar) point of the bone (this is also the deepest – dorso-palmar - point of the 3<sup>rd</sup> metatarsal).

Distal: Just distal of the distal fusion line, at the midpoint (medio-laterally) of the 3<sup>rd</sup> metatarsal.

Shaft: Halfway between the proximal and distal scan-sites, at the medio-lateral centre of the 3<sup>rd</sup> metatarsal.

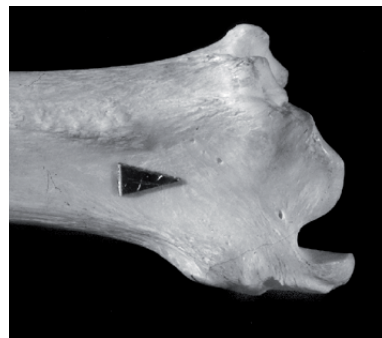
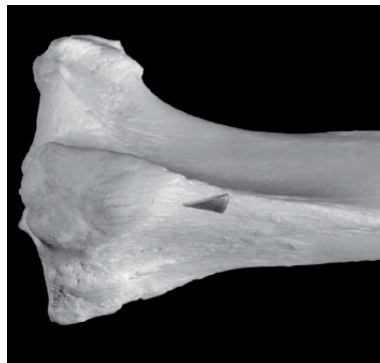
### **Tibia**

Proximal: Just distal of the proximal fusion line, immediately medial to the deepest (dorso-plantar) point of the bone (the tibial tuberosity).

Distal: Just proximal of the distal fusion line, in the medio-lateral centre of the groove for the flexor hallicis longus.

Shaft: Halfway between the proximal and distal scan-sites at the medio-lateral centre of the bone.

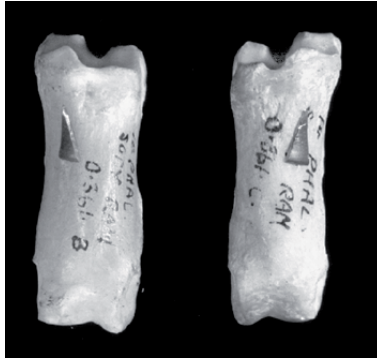

### **Left and right lateral first phalanx**

One measurement only: Just distal of the most distal point of the articulation for the lateral condyle of the metapodia, distal to the articulation for the lateral epicondyle.

### **Left and right medial first phalanx**

One measurement only: Just distal of the most distal part of the articulation for the medial condyle of the metapodia, distal to the articulation for the medial epicondyle.



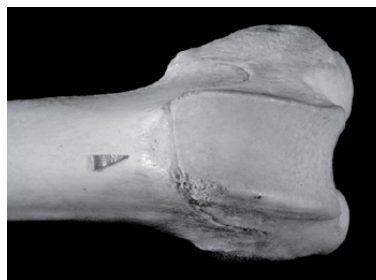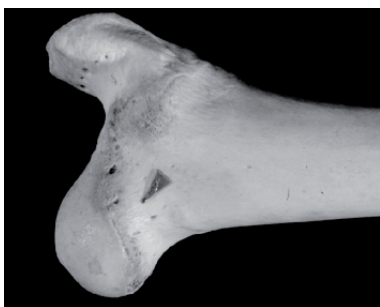## Femur

Proximal: At the neck of the femur, just distal of the fusion line for the femoral head and midway between the disto-medial and the proximo-lateral edges of the femoral neck. Due to the morphology of this part of this bone, it was impossible to position the scan-site immediately adjacent to the proximal fusion plane. Instead, a position more distal to the diagnostic zone was selected. It should be noted that archaeological material exhibiting this diagnostic zone invariably included this scan-site also.

Consequently this decision had no impact on the quantification of the archaeological material (see section 7.1.3).

Distal: Just proximal of the distal fusion line, at the medio-lateral centre of the bone.

Shaft: Halfway between the proximal and distal scan-sites, at the medio-lateral centre of the bone.



## **Pelvis**

One measurement only: Cranial to the acetabulum, at the anterior inferior illiac spine.

