





SITE CODE: Sox 19

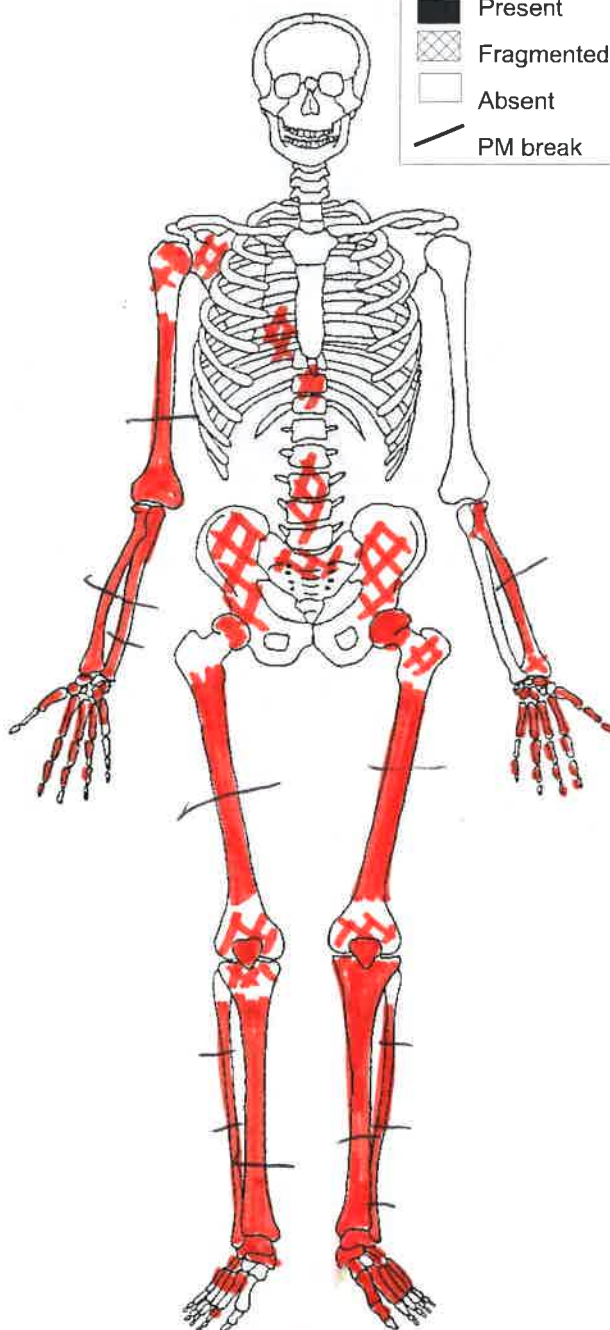
SKELETON NO: 6008

RECORDER: MG

DATE: 7/9/20

BONE PRESENCE/ABSENCE

	Present
	Fragmented
	Absent
	PM break



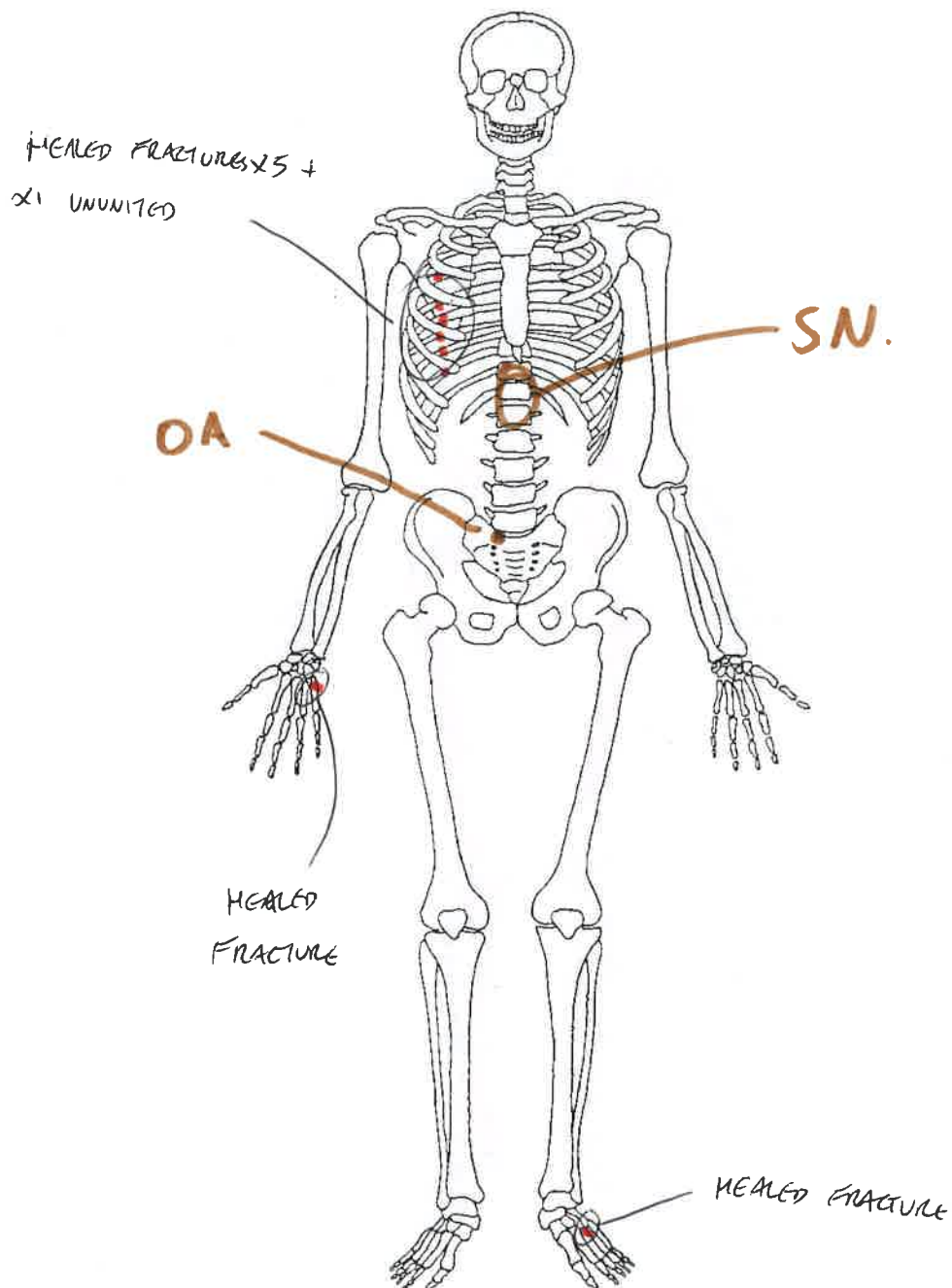
SITE CODE: 50X19

SKELETON NO: 6008

RECORDER: MG

DATE: 7/9/20

PATHOLOGY



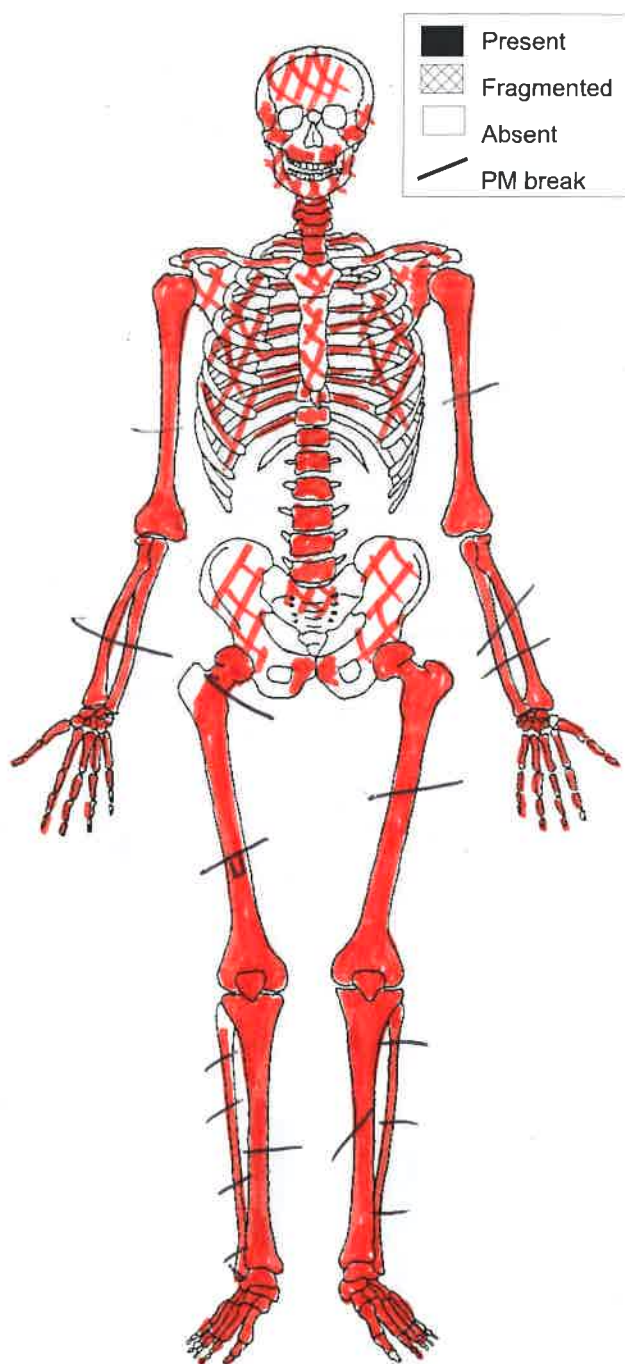
SITE CODE: 50X19

SKELETON NO: 6011

RECORDER: Mg

DATE: 9/9/20

BONE PRESENCE/ABSENCE



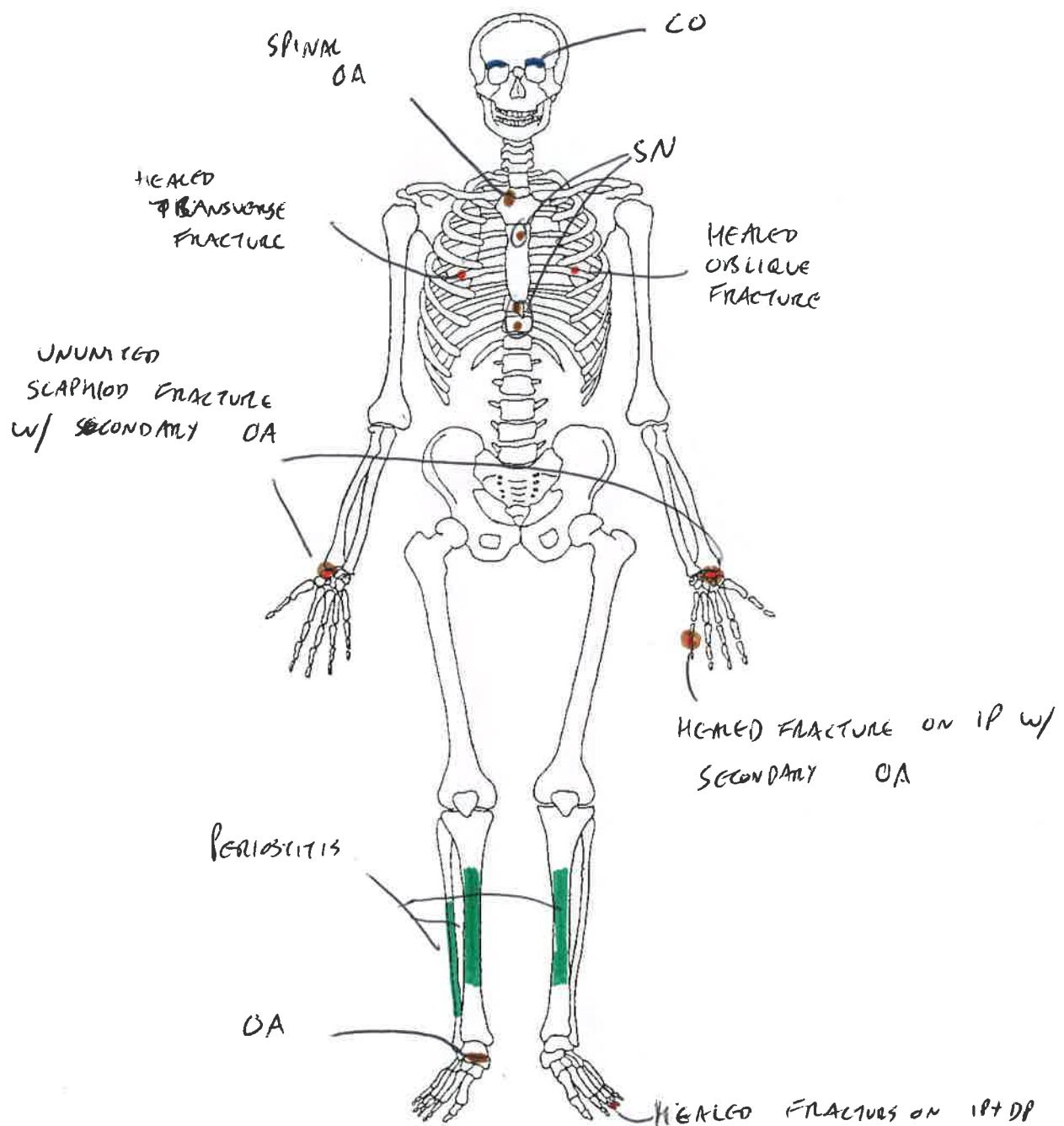
SITE CODE: Sox19

SKELETON NO: 6011

RECORDER: MG

DATE: 9/9/20

PATHOLOGY







SITE CODE: 50X19

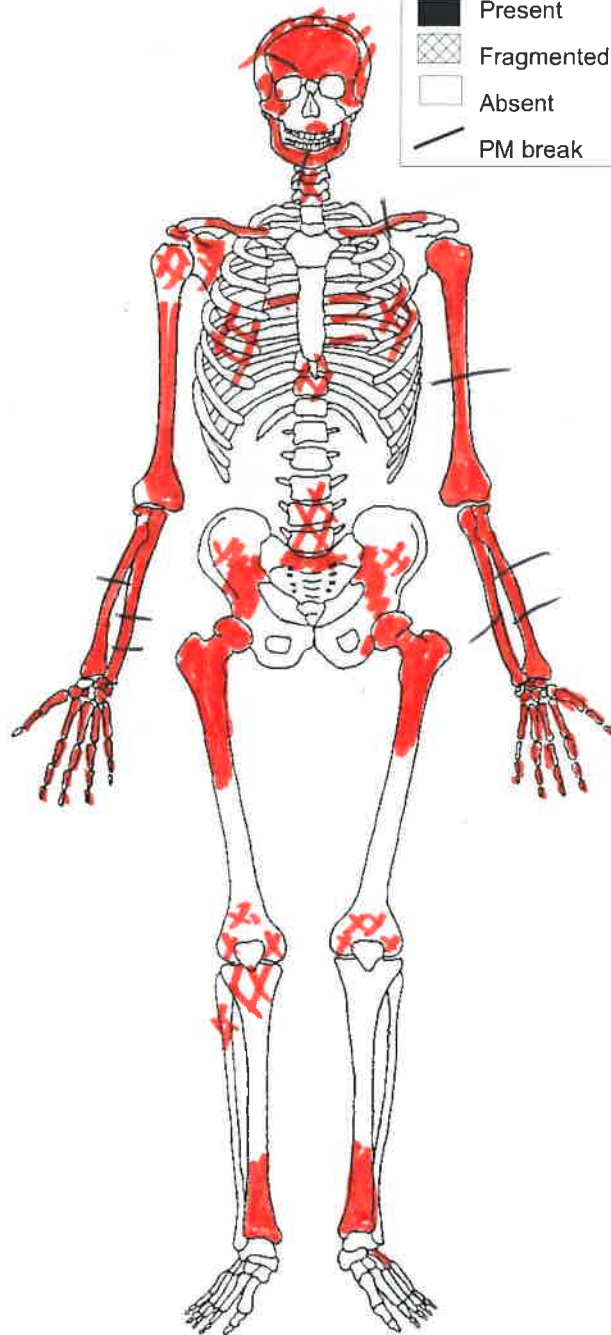
SKELETON NO: 6015

RECORDER: M4

DATE: 9/9/20

BONE PRESENCE/ABSENCE

	Present
	Fragmented
	Absent
	PM break

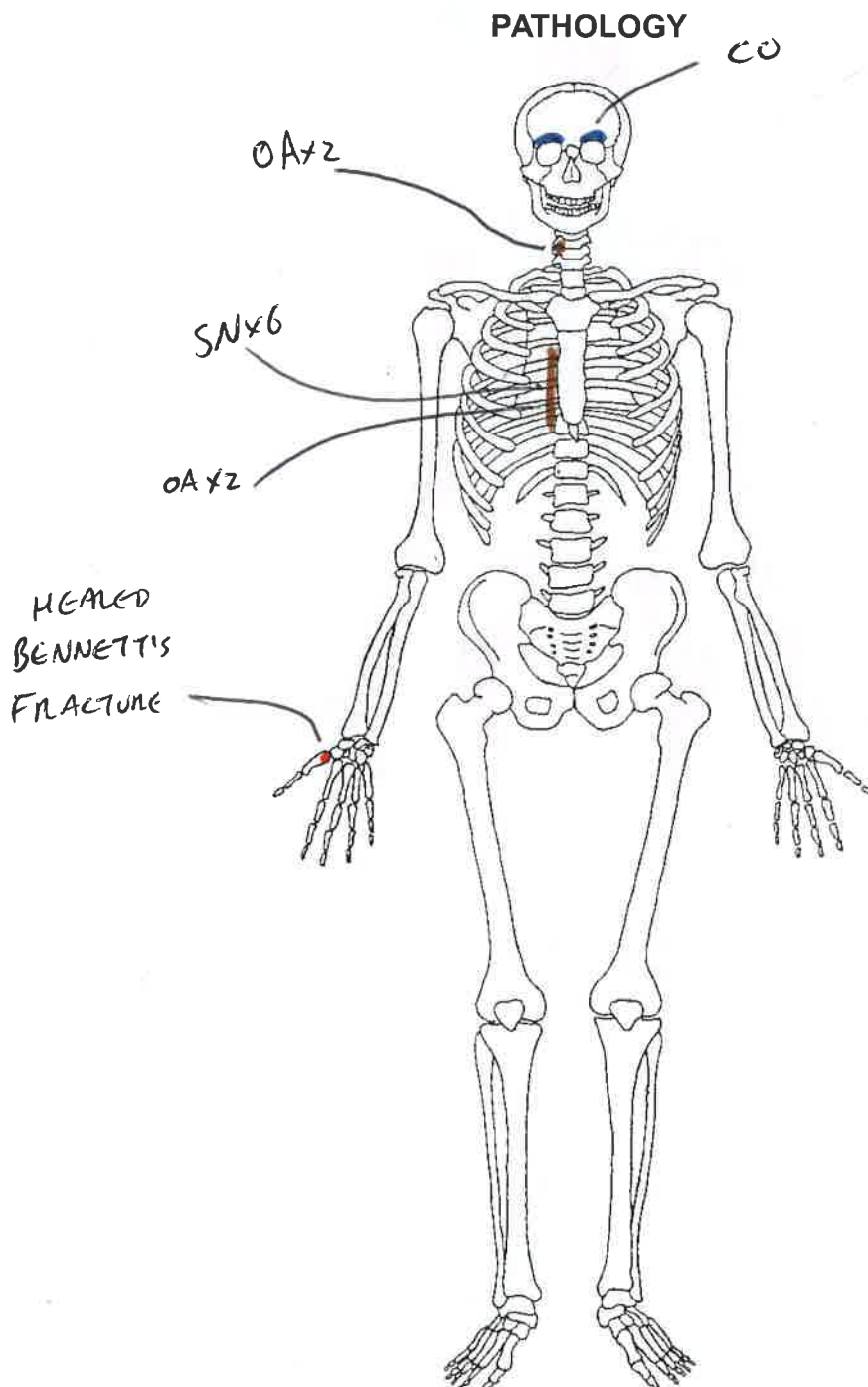


SITE CODE: 50x19

SKELETON NO: 6015

RECORDER: M4

DATE: 9/9/20



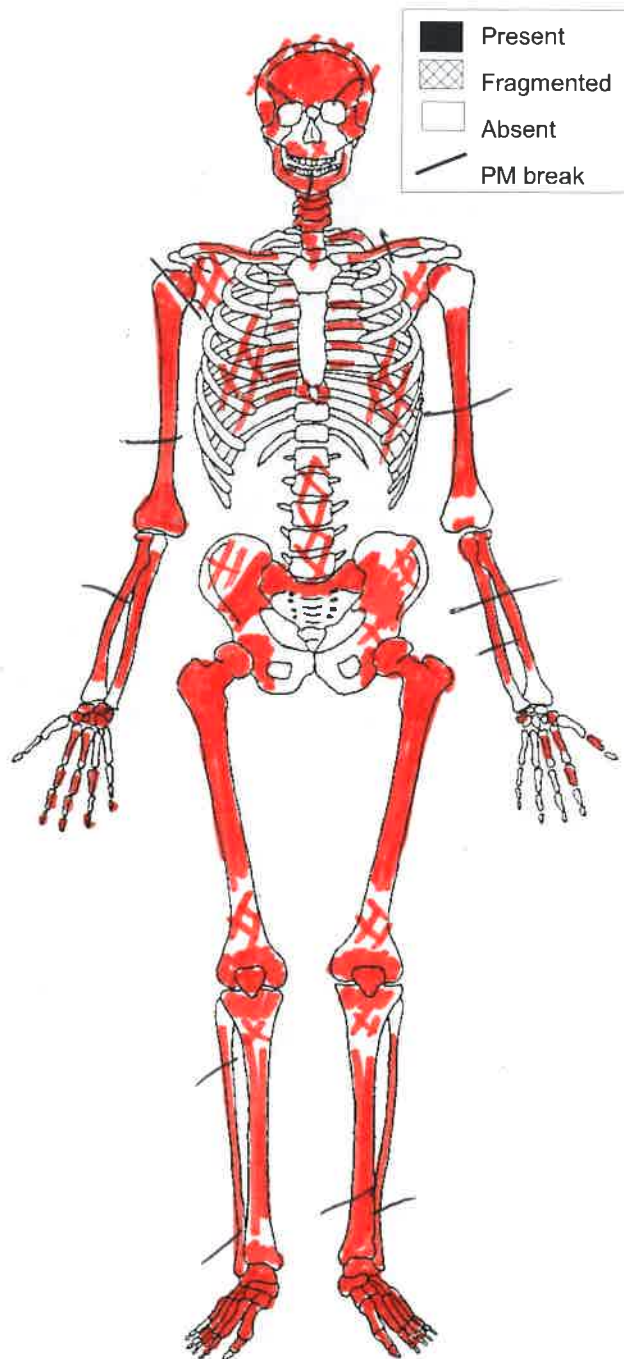
SITE CODE: Sox 19

SKELETON NO: 6022

RECORDER: MG

DATE: 8/9/20

BONE PRESENCE/ABSENCE



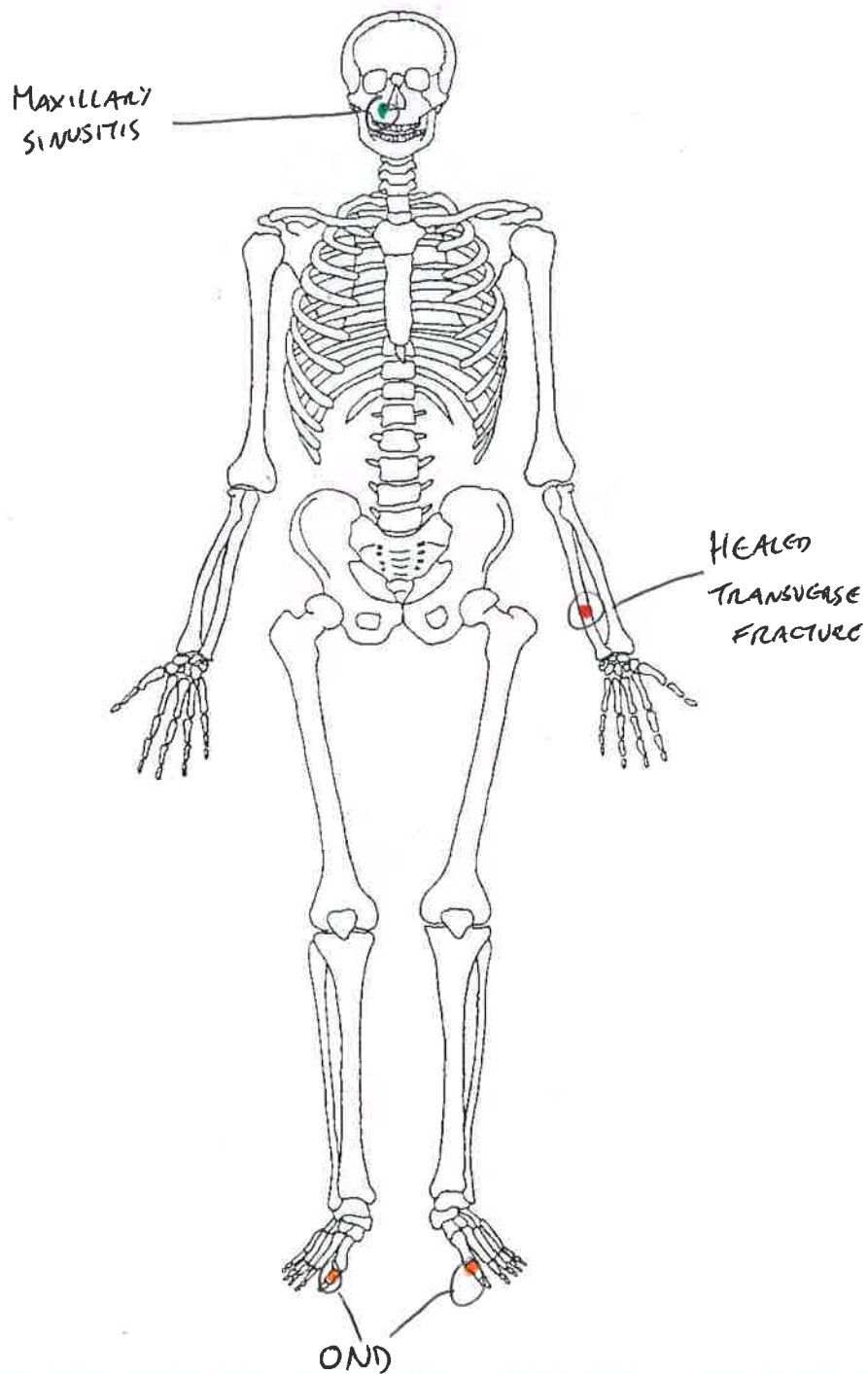
SITE CODE: 50X19

SKELETON NO: 6022

RECORDER: MG

DATE: 8/9/20

PATHOLOGY







SITE CODE: 50X19

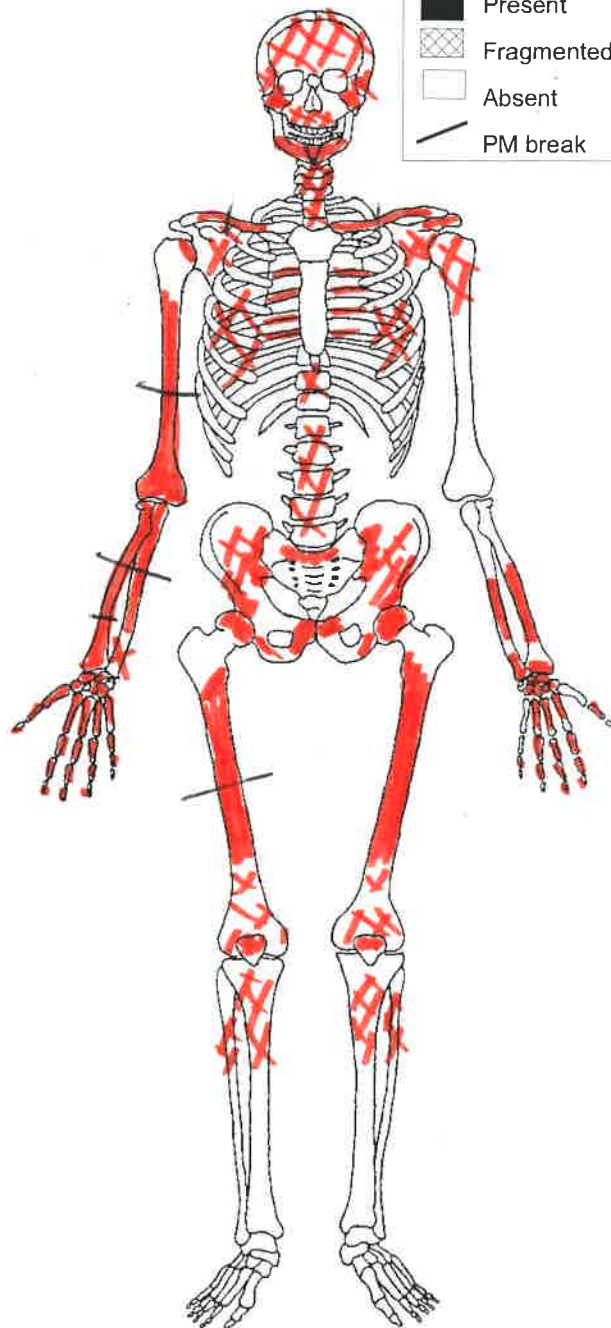
SKELETON NO: 6026

RECORDER: MG

DATE: 8/9/20

BONE PRESENCE/ABSENCE

	Present
	Fragmented
	Absent
	PM break



SITE CODE: 50x19

SKELETON NO: 6026

RECORDER: M4

DATE: 8/9/20

PATHOLOGY

